

# Guidelines for the Management of Traumatic Dental Injuries: 2. Avulsion of Permanent Teeth

## Originating Group

International Association of Dental Traumatology

## Endorsed by the American Academy of Pediatric Dentistry

2013

Lars Andersson<sup>\*1</sup> • Jens O. Andreasen<sup>\*2</sup> • Peter Day<sup>\*3</sup> • Geoffrey Heithersay<sup>\*4</sup> • Martin Trope<sup>\*5</sup> • Anthony J. DiAngelis<sup>6</sup> • David J. Kenny<sup>7</sup> • Asgeir Sigurdsson<sup>8</sup> • Cecilia Bourguignon<sup>9</sup> • Marie Therese Flores<sup>10</sup> • Morris Lamar Hicks<sup>11</sup> • Antonio R. Lenzi<sup>12</sup> • Barbro Malmgren<sup>13</sup> • Alex J. Moule<sup>14</sup> • Mitsuhiro Tsukiboshi<sup>15</sup>

**Abstract:** Avulsion of permanent teeth is one of the most serious dental injuries, and a prompt and correct emergency management is very important for the prognosis. The International Association of Dental Traumatology (IADT) has developed a consensus statement after a review of the dental literature and group discussions. Experienced researchers and clinicians from various specialties were included in the task group. The guidelines represent the current best evidence and practice based on literature research and professionals' opinion. In cases where the data did not appear conclusive, recommendations were based on the consensus opinion or majority decision of the task group. Finally, the IADT board members were giving their opinion and approval. The primary goal of these guidelines is to delineate an approach for the immediate or urgent care of avulsed permanent teeth. (*Dental Traumatology* 2012;28:88-96; doi:10.1111/j.1600-9657.2012.01125.x) Accepted January 30, 2012

KEYWORDS: AVULSION, EXARTICULATION, CONSENSUS, REVIEW, TRAUMA, TOOTH

<sup>1</sup>Department of Surgical Sciences, Faculty of Dentistry, Health Sciences Center, Kuwait University, Kuwait City, Kuwait; <sup>2</sup>Department of Oral and Maxillofacial Surgery, Center of Rare Oral Diseases, Copenhagen University Hospital, Rigshospitalet, Copenhagen, Denmark; <sup>3</sup>Paediatric Dentistry, Leeds Dental Institute and Bradford District Care Trust Salaried Dental Service, Leeds, UK; <sup>4</sup>Faculty of Health Sciences, School of Dentistry, Endodontology, The University of Adelaide, Adelaide, SA, Australia; <sup>5</sup>Department of Endodontics, School of Dentistry, University of Pennsylvania, Philadelphia, PA, USA; <sup>6</sup>Department of Dentistry, Hennepin County Medical Center and University of Minnesota School of Dentistry, Minneapolis, MN, USA; <sup>7</sup>Hospital for Sick Children and University of Toronto, Toronto, ON, Canada; <sup>8</sup>Department of Endodontics, UNC School of Dentistry, Chapel Hill, NC, USA; <sup>9</sup>Private Practice, Paris, France; <sup>10</sup>Department of Pediatric Dentistry, Faculty of Dentistry, Universidad de Valparaíso, Valparaíso, Chile; <sup>11</sup>Department of Endodontics, University of Maryland School of Dentistry, Baltimore, MD, USA; <sup>12</sup>Private Practice, Rio de Janeiro, Brazil; <sup>13</sup>Division of Pediatrics, Department of Clinical Sciences Intervention and Technology, Karolinska University Hospital, Stockholm, Sweden; <sup>14</sup>Private Practice, University of Queensland, Brisbane, Qld, Australia; <sup>15</sup>Private Practice, Amagun, Aichi, Japan

Correspondence to Lars Andersson, DDS, PhD, DrOdont, Oral & Maxillofacial Surgery, Department of Surgical Sciences, Health Sciences Center, P.O. Box 24923, Safat 13110, Kuwait.

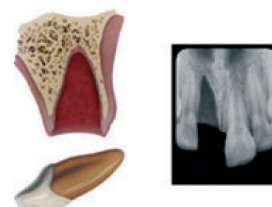
Tel.: +965 24986695

Fax: +965 24986732

e-mail: dr.lars.andersson@gmail.com

\* Members of the Task Group.

Whenever referring to IADT Guidelines, the original article, (*Dent Traumatol* 2012;28:88-96) should always be used as reference.



Avulsion of permanent teeth is seen in 0.5–3% of all dental injuries (1, 2). Numerous studies show that this injury is one of the most serious dental injuries, and the prognosis is very much dependent on the actions taken at the place of accident and promptly after the avulsion (2–27). Replantation is in most situations the treatment of choice, but cannot always be carried out immediately. An appropriate emergency management and treatment plan are important for a good prognosis. There are also individual situations when replantation is not indicated (e.g., severe caries or periodontal disease, non-cooperating patient, severe medical conditions (e.g., immunosuppression and severe cardiac conditions) which must be dealt with individually. Replantation may successfully save the tooth, but it is important to realize that some of the replanted teeth have lower chances of long-term survival and may even be lost or extracted at a later stage.

Guidelines for the emergency management are useful for delivering the best care possible in an efficient manner. The International Association of Dental Traumatology (IADT) has developed a consensus statement after an update of the dental literature and discussions in expert groups. Experienced international researchers and

clinicians from various specialties and general dentistry were included in the groups. In cases in which the data did not appear conclusive, recommendations were based on the consensus opinion and in some situations on majority decision among the IADT board members. All recommendations are not evidence based on a high level. The guidelines should therefore be seen as the current best evidence and practice based on literature research and professionals' opinion.

Guidelines should assist dentists, other healthcare professionals, and patients in decision making. Also, they should be credible, readily understandable, and practical with the aim of delivering appropriate care as effectively and efficiently as possible.

It is understood that guidelines are to be applied with judgment of the specific clinical circumstances, clinicians' judgments, and patients' characteristics, including, but not limited to compliance, finances and understanding of the immediate and long-term outcomes of treatment alternatives vs non-treatment. The IADT cannot and does not guarantee favorable outcomes from strict adherence to the Guidelines, but believe that their application can maximize the chances of a favorable outcome. Guidelines undergo periodic updates. The following guidelines by the IADT represent an updated set of guidelines based on the original guidelines published in 2007 (28–30).

In this article, one of a series of three articles, the IADT Guidelines for management of avulsed permanent teeth are presented. Literature has been searched using Medline and Scopus databases using the search words: avulsion, exarticulation, and replantation. The task group has then discussed the emergency treatment in detail and reached consensus of what to recommend today as best practice for the emergency management. This text is aiming at giving the concise, short necessary advice for treatment in the emergency situation. More detailed description of protocols, methods, and documentation for clinical assessment and diagnosis of different dental injuries can be found in articles, textbooks, and manuals (2, 24) and in the interactive web site Dental Trauma Guide <http://dentaltrauma.guide.org>.

The final decision regarding patient care remains primarily in the hand of the treating dentist. For ethical reasons, it is important that the dentist provides the patient and guardian with pertinent information relating to treatment so also the patient and guardian has as much influence in the decision-making process as possible.

#### **First aid for avulsed teeth at the place of accident (2, 10, 24, 25, 31–55)**

Dentists should always be prepared to give appropriate advice to the public about first aid for avulsed teeth. An avulsed permanent tooth is one of the few real emergency situations in dentistry. In addition to increasing the public awareness by, for example, mass media campaigns, healthcare professionals, guardians and teachers should receive information on how to proceed following these severe unexpected injuries. Also, instructions may be given by telephone to people at the emergency site. Immediate replantation is the best treatment at the place of accident. If for some

reasons this cannot be carried out, there are alternatives such as using various storage media.

If a tooth is avulsed, make sure it is a permanent tooth (primary teeth should not be replanted).

- Keep the patient calm.
- Find the tooth and pick it up by the crown (the white part). Avoid touching the root.
- If the tooth is dirty, wash it briefly (max 10 s) under cold running water and reposition it. Try to encourage the patient/guardian to replant the tooth. Once the tooth is back in place, bite on a handkerchief to hold it in position.
- If this is not possible, or for other reasons when replantation of the avulsed tooth is not possible (e.g., an unconscious patient), place the tooth in a glass of milk or another suitable storage medium and bring with the patient to the emergency clinic. The tooth can also be transported in the mouth, keeping it inside the lip or cheek if the patient is conscious. If the patient is very young, he/she could swallow the tooth – therefore it is advisable to get the patient to spit in a container and place the tooth in it. Avoid storage in water!
- If there is access at the place of accident to special storage or transport media (e.g., tissue culture/transport medium, Hanks balanced storage medium (HBSS) or saline) such media can preferably be used.
- Seek emergency dental treatment immediately.

The poster 'Save a Tooth' is written for the public and is available in several languages: English, Spanish, Portuguese, French, Icelandic, Italian, Arabic, and Turkish and can be obtained at the IADT website: <http://www.iadt-dentaltrauma.org>.

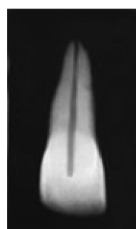#### **Treatment guidelines for avulsed permanent teeth (56–95)**

Choice of treatment is related to the maturity of the root (open or closed apex) and the condition of the periodontal ligament cells. The condition of the cells is depending on the storage medium and the time out of the mouth, especially the dry time is critical for survival of the cells. After a dry time of 60 min or more, all periodontal ligament (PDL) cells are non-viable. For this reason, the dry time of the tooth, before it was placed replanted or placed in a storage medium, is very important to assess from the patient's history.

From a clinical point of view, it is important for the clinician to roughly assess the condition of the cells by classifying the avulsed tooth into one of the following three groups before starting treatment:

- The PDL cells are most likely viable (i.e., the tooth has been replanted immediately or after a very short time at the place of accident).
- The PDL cells may be viable but compromised. The tooth has been kept in storage medium (e.g., tissue culture medium, HBSS, saline, milk, or saliva and the total dry time has been < 60 min).
- The PDL cells are non-viable. Examples of this is when the trauma history tells us that the total extra-oral dry time has been more than 60 min regardless of if the tooth was stored in an additional medium or not, or if the storage medium was non-physiologic.

## 1. Treatment guidelines for avulsed permanent teeth with closed apex



### 1a. The tooth has been replanted before the patient's arrival at the clinic

- Leave the tooth in place.
- Clean the area with water spray, saline, or chlorhexidine.
- Suture gingival lacerations, if present.
- Verify normal position of the replanted tooth both clinically and radiographically.
- Apply a flexible splint for up to 2 weeks (see Splinting).
- Administer systemic antibiotics (see Antibiotics).
- Check tetanus protection (see Tetanus).
- Give patient instructions (see Patient instructions).
- Initiate root canal treatment 7–10 days after replantation and before splint removal. (see Endodontic considerations).

#### Follow-up

See: Follow-up procedures.

### 1b. The tooth has been kept in a physiologic storage medium or osmolality balanced medium and/or stored dry, the extra-oral dry time has been less than 60 min

*Physiologic storage media* include tissue culture medium and cell transport media. Examples of *osmolality balanced media* are HBSS, saline, and milk. Saliva can also be used.

- Clean the root surface and apical foramen with a stream of saline and soak the tooth in saline thereby removing contamination and dead cells from the root surface.
- Administer local anesthesia.
- Irrigate the socket with saline.
- Examine the alveolar socket. If there is a fracture of the socket wall, reposition it with a suitable instrument.
- Replant the tooth slowly with slight digital pressure. Do not use force.
- Suture gingival lacerations, if present.
- Verify normal position of the replanted tooth both clinically and radiographically.
- Apply a flexible splint for up to 2 weeks, keep away from the gingiva.
- Administer systemic antibiotics (see Antibiotics).
- Check tetanus protection (see Tetanus).
- Give patient instructions (see Patient instructions).
- Initiate root canal treatment 7–10 days after replantation and before splint removal (see Endodontic considerations).

#### Follow-up

See: Follow-up procedures.

### 1c. Dry time longer than 60 min or other reasons suggesting non-viable cells

Delayed replantation has a poor long-term prognosis. The periodontal ligament will be necrotic and not expected to heal. The goal in delayed replantation is, in addition to restoring the tooth for esthetic, functional and psychological reasons, to maintain alveolar bone contour. However, the expected eventual outcome is ankylosis and resorption of the root and the tooth will be lost eventually.

The technique for delayed replantation is as follows:

- Remove attached non-viable soft tissue carefully, for example, with gauze. The best way to this has not yet been decided (see Future areas of research).
- Root canal treatment to the tooth can be carried out prior to replantation or later (see Endodontic considerations).
- In cases of delayed replantation, root canal treatment should be either carried out on the tooth prior to replantation or it can be carried out 7–10 days later like in other replantation situations (see Endodontic considerations).
- Administer local anesthesia.
- Irrigate the socket with saline.
- Examine the alveolar socket. If there is a fracture of the socket wall, reposition it with a suitable instrument.
- Replant the tooth.
- Suture gingival lacerations, if present.
- Verify normal position of the replanted tooth clinically and radiographically.
- Stabilize the tooth for 4 weeks using a flexible splint (see Splinting).
- Administration of systemic antibiotics (see Antibiotics).
- Check tetanus protection (see Tetanus).
- Give patient instructions (see Patient instructions).

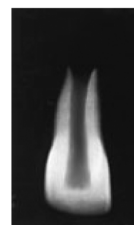
To slow down osseous replacement of the tooth, treatment of the root surface with fluoride prior to replantation has been suggested (2% sodium fluoride solution for 20 min) but it should not be seen as an absolute recommendation.

#### Follow-up

See: Follow-up procedures.

In children and adolescents ankylosis is frequently associated with infra-position. Careful follow-up is required and good communication is necessary to ensure the patient and guardian of this likely outcome. Decoronation may be necessary later when infraposition (> 1 mm) is seen. For more detailed information of this procedure, the reader is referred to textbooks.

## 2. Treatment guidelines for avulsed permanent teeth with an open apex





**2a. The tooth has been replanted before the patient's arrival at the clinic**

- Leave the tooth in place.
- Clean the area with water spray, saline, or chlorhexidine.
- Suture gingival lacerations, if present.
- Verify normal position of the replanted tooth both clinically and radiographically.
- Apply a flexible splint for up to 2 weeks (see Splinting).
- Administer systemic antibiotics (see Antibiotics).
- Check tetanus protection (see Tetanus).
- Give patient instructions (see Patient instructions).
- The goal for replanting still-developing (immature) teeth in children is to allow for possible revascularization of the pulp space. If that does not occur, root canal treatment may be recommended (see Endodontic considerations).

*Follow-up*

See: Follow-up procedures.

**2b. The tooth has been kept in a physiologic storage medium or osmolality balanced medium and/or stored dry, the extra-oral dry time has been <60 min**

*Physiologic storage media* include tissue culture medium and cell transport media. Examples of *osmolality balanced media* are HBSS, saline, and milk. Saliva can also be used.

- If contaminated, clean the root surface and apical foramen with a stream of saline.
- Topical application of antibiotics has been shown to enhance chances for revascularization of the pulp and can be considered if available (see Antibiotics).
- Administer local anesthesia.
- Examine the alveolar socket.
- If there is a fracture of the socket wall, reposition it with a suitable instrument.
- Remove the coagulum in the socket and replant the tooth slowly with slight digital pressure.
- Suture gingival lacerations, especially in the cervical area.
- Verify normal position of the replanted tooth clinically and radiographically. Apply a flexible splint for up to 2 weeks (see Splinting).
- Administer systemic antibiotics (see Antibiotics).
- Check tetanus protection (see Tetanus).
- Give patient instructions (see Patient instructions).
- The goal for replanting still-developing (immature) teeth in children is to allow for possible revascularization of the pulp space. The risk of infection-related root resorption should be weighed up against the chances of revascularization. Such resorption is very rapid in teeth of children. If revascularization does not occur, root canal treatment may be recommended (see Endodontic considerations).

*Follow-up*

See Follow-up procedures.

**2c. Dry time longer than 60 min or other reasons suggesting non-viable cells**

Delayed replantation has a poor long-term prognosis. The periodontal ligament will be necrotic and not expected to heal. The goal in delayed replantation is to restore the tooth

to the dentition for esthetic, functional, and psychological reasons and to maintain alveolar contour. The eventual outcome will be ankylosis and resorption of the root.

The technique for delayed replantation is as follows:

- Remove attached non-viable soft tissue carefully, for example, with gauze. The best way to this has not yet been decided (see Future areas of research).
- Root canal treatment to the tooth can be carried out prior to replantation or later (see Endodontic considerations).
- Administer local anesthesia.
- Remove the coagulum from the socket with a stream of saline. Examine the alveolar socket. If there is a fracture of the socket wall, reposition it with a suitable instrument.
- Replant the tooth slowly with slight digital pressure. Suture gingival laceration. Verify normal position of the replanted tooth clinically and radiographically.
- Stabilize the tooth for 4 weeks using a flexible splint (see Splinting).
- Administer systemic antibiotics (see Antibiotics).
- Check tetanus protection (see Tetanus).
- Give patient instructions (see Patient instructions).

To slow down osseous replacement of the tooth, treatment of the root surface with fluoride prior to replantation (2% sodium fluoride solution for 20 min) has been suggested but it should not be seen as an absolute recommendation.

*Follow-up*

See Follow-up procedures.

Ankylosis is unavoidable after delayed replantation and must be taken into consideration.

In children and adolescents ankylosis is frequently associated with infraposition. Careful follow-up is required and good communication is necessary to ensure the patient and guardian of this likely outcome. Decoronation may be necessary when infraposition (> 1 mm) is seen. For more detailed information of this procedure the reader is referred to textbooks.

**Anesthetics (64–66)**

Patients and guardians are recommended by us to do replantation at the place of accident without anesthesia. In the clinic, however, where local anesthetics are available, there is no need to omit local anesthesia, especially as there are often concomitant injuries. Concern is sometimes raised whether there are risks of compromising healing by using vasoconstrictor in the anesthesia. Evidence is weak for omitting vasoconstrictor in the oral and maxillofacial region and must be further documented before any recommendations against the use of it can be given (see suggested future areas of research at the end of this article). Block anesthesia (e.g., infra-orbital nerve block) may be considered as an alternative to infiltration anesthesia in more severely injured areas and must be related to the clinicians' experience of such blocking techniques.

**Antibiotics (67–76)**

The value of systemic administration of antibiotics in human after replantation is still questionable as clinical studies have not demonstrated its value. Experimental

studies have, however, usually shown positive effects upon both periodontal and pulpal healing especially when administered topically. For this reason, antibiotics are in most situations recommended after replantation of teeth. In addition, the patient's medical status or concomitant injuries may warrant antibiotic coverage.

For systemic administration, tetracycline is the first choice in appropriate dose for patient age and weight the first week after replantation. The risk of discoloration of permanent teeth must be considered before systemic administration of tetracycline in young patients. In many countries, tetracycline is not recommended for patients under 12 years of age. A penicillin phenoxymethylpenicillin (Pen V) or amoxycillin, in an appropriate dose for age and weight the first week, can be given as alternative to tetracycline.

Topical antibiotics (minocycline or doxycycline, 1 mg per 20 ml of saline for 5 min soak) appear experimentally to have a beneficial effect in increasing the chance of pulpal space revascularization and periodontal healing and may be considered in immature teeth (2b).

### **Tetanus (2, 24, 25)**

Refer the patient to a physician for evaluation of need for a tetanus booster if the avulsed tooth has contacted soil or tetanus coverage is uncertain.

### **Splinting of replanted teeth (77–83)**

It is considered best practice to maintain the repositioned tooth in correct position, provide patient comfort and improve function. Current evidence supports short-term, flexible splints for splinting of replanted teeth. Studies have shown that periodontal and pulpal healing is promoted if the replanted tooth is given a chance for slight motion and the splinting time is not too long. Given this there is so far no specific type of splint related to healing outcomes. The splint should be placed on the buccal surfaces of the maxillary teeth to enable lingual access for endodontic procedures and to avoid occlusal interference.

Replanted permanent teeth should be splinted up to 2 weeks. Various types of acid etch bonded splints have been widely used to stabilize avulsed teeth because they allow good oral hygiene and are well tolerated by the patients. For a detailed description of how to make a splint, the reader is referred to articles, textbooks, manuals, and the web site Dental Trauma Guide <http://www.dentaltraumaguide.org>.

### **Patient instructions (2, 24, 25)**

Patient compliance with follow-up visits and home care contributes to satisfactory healing following an injury. Both patients and guardians of young patients should be advised regarding care of the replanted tooth for optimal healing and prevention of further injury.

- Avoid participation in contact sports.
- Soft diet for up to 2 weeks. Thereafter normal function as soon as possible.
- Brush teeth with a soft toothbrush after each meal.
- Use a chlorhexidine (0.1%) mouth rinse twice a day for 1 week.

### **Endodontic considerations (62, 84–93)**

If root canal treatment is indicated (teeth with closed apex), the ideal time to begin treatment is 7–10 days postreplantation. Calcium hydroxide is recommended as an intra-canal medication for up to 1 month followed by root canal filling with an acceptable material. Alternatively if an antibiotic-corticosteroid paste is chosen to be used as an anti-inflammatory, anti-clastic intra-canal medicament, it may be placed immediately or shortly following replantation and left for at least 2 weeks. If the antibiotic in the paste is dechlorotetracycline, there is a risk of tooth discoloration and care should be taken to confine the paste to the root canal and avoid contact of the paste with the pulp chamber walls.

If the tooth has been dry for more than 60 min before replantation. The root canal treatment may be carried out extra-orally prior to replantation.

In teeth with open apices, which have been replanted immediately or kept in appropriate storage media prior to replantation, pulp revascularization is possible. The risk of infection-related root resorption should be weighed up against the chances of obtaining pulp space revascularization. Such resorption is very rapid in teeth of children. For very immature teeth, root canal treatment should be avoided unless there is clinical or radiographic evidence of pulp necrosis.

### **Follow-up procedures (2, 6–9, 24, 25)**

#### **Clinical control**

Replanted teeth should be monitored by clinical and radiographic control after 4 weeks, 3 months, 6 months, 1 year, and yearly thereafter. Clinical and radiographic examination will provide information to determine outcome. Evaluation may include the findings described as follows.

#### **Favorable outcome**

##### *Closed apex*

Asymptomatic, normal mobility, normal percussion sound. No radiographic evidence of resorption or periradicular osteitis: the lamina dura should appear normal.

##### *Open apex*

Asymptomatic, normal mobility, normal percussion sound. Radiographic evidence of arrested or continued root formation and eruption. Pulp canal obliteration is to be expected.

#### **Unfavorable outcome**

##### *Closed apex*

Symptomatic, excessive mobility or no mobility (ankylosis) with high-pitched percussion sound. Radiographic evidence of resorption (inflammatory, infection-related resorption, or ankylosis-related replacement resorption). When ankylosis occurs in a growing patient, infraposition of the tooth is highly likely leading to disturbance in alveolar and facial growth over the short-, medium-, and long term.

### Open apex

Symptomatic, excessive mobility or no mobility (ankylosis) with high-pitched percussion sound. In the case of ankylosis, the crown of the tooth will appear to be in an infraposition. Radiographic evidence of resorption (inflammatory, infection-related resorption, or ankylosis-related replacement resorption) or absence of continued root formation. When ankylosis occurs in a growing patient, infraposition of the tooth is highly likely to occur leading to disturbance of alveolar and facial growth over the short-, medium-, and long term.

### Loss of tooth

In cases where teeth are lost in the emergency phase or will be lost later after trauma, discussions with colleagues, where available, who have expertise with managing such cases is prudent especially in growing patients. Ideally these discussions should take place before the tooth shows signs of infraposition. Appropriate treatment options may include decoronation, auto-transplantation, resin retained bridge, denture, orthodontic space closure with composite modification and sectional osteotomy. Such treatment decisions are based on a full discussion with the child and parents, clinician's expertise and aim to keep all options open until maturity is reached. After growth is completed, implant treatment can also be considered. The clinician is referred to textbooks and articles for further readings regarding these procedures.

### Future areas of research – methods discussed but not included as recommendations in the guidelines this time

A number of promising treatment procedures for avulsed teeth have been discussed in the consensus group. Some of these treatment suggestions do have certain experimental evidence, and some of them are even used today in clinical practice: according to the group members, there is currently insufficient weight or quality of clinical and/or experimental evidence for some of these methods to be recognized as recommendations in the guidelines this time. These and some other important fields are examples where the group advocates further research and documentation:

- Methods for removal of non-viable PDL.
- Conditioning the PDL with extra-oral storage in tissue culture media prior to replantation.
- Conditioning the PDL with enamel matrix protein prior to replantation for teeth with short extra-oral periods.
- Topical treatment of root surface with fluoride for teeth with long extra-oral period.
- Revascularization of pulp space and methods promoting this.
- Optimal splint types with regard to periodontal and pulpal healing.
- Effect on adrenaline content of local anesthesia on healing.
- Reducing the inflammation with corticosteroids.
- Extra-oral root filling of teeth with less than a 60 min drying period.
- Use of titanium posts for root elongation and as alternatives to conventional root canal treatment.
- Long-term development of alveolar crest following replantation and decoronation.

### Acknowledgement

The authors wish to express their gratefulness to the Dental Trauma Guide team in Copenhagen, Denmark <http://www.dentaltraumaguide.org> for permission to use their illustrations for this article.

### References

1. Glendor U, Halling A, Andersson L, Eilert-Peterson E. Incidence of traumatic tooth injuries in children and adolescents in the county of Västmanland, Sweden. *Swed Dent J* 1996;20:15–28.
2. Andreasen JO, Andreasen FM. Avulsions. In: Andreasen JO, Andreasen FM, Andersson L, editors. Textbook and color atlas of traumatic injuries to the teeth, 4th edn. Oxford, UK: Wiley-Blackwell; 2007. p. 444–88.
3. Andreasen JO, Hjorting-Hansen E. Replantation of teeth. I. Radiographic and clinical study of 110 human teeth replanted after accidental loss. *Acta Odontol Scand* 1966;24: 263–86.
4. Andersson L, Bodin I, Sorensen S. Progression of root resorption following replantation of human teeth after extended extraoral storage. *Endod Dent Traumatol* 1989;5:38–47.
5. Andersson L, Bodin I. Avulsed human teeth replanted within 15 minutes – a long-term clinical follow-up study. *Endod Dent Traumatol* 1990;6:37–42.
6. Andreasen JO, Borum MK, Jacobsen HL, Andreasen FM. Replantation of 400 avulsed permanent incisors. 1. Diagnosis of healing complications. *Endod Dent Traumatol* 1995;11:51–8.
7. Andreasen JO, Borum MK, Jacobsen HL, Andreasen FM. Replantation of 400 avulsed permanent incisors. 2. Factors related to pulpal healing. *Endod Dent Traumatol* 1995;11:59–68.
8. Andreasen JO, Borum MK, Andreasen FM. Replantation of 400 avulsed permanent incisors. 3. Factors related to root growth. *Endod Dent Traumatol* 1995;11:69–75.
9. Andreasen JO, Borum MK, Jacobsen HL, Andreasen FM. Replantation of 400 avulsed permanent incisors. 4. Factors related to periodontal ligament healing. *Endod Dent Traumatol* 1995;11:76–89.
10. Barrett EJ, Kenny DJ. Avulsed permanent teeth: a review of the literature and treatment guidelines. *Endod Dent Traumatol* 1997;13:153–63.
11. Barrett EJ, Kenny DJ. Survival of avulsed permanent maxillary incisors in children following delayed replantation. *Endod Dent Traumatol* 1997;13:269–75.
12. Ebeleseder KA, Friehs S, Ruda C, Pertl C, Glockner K, Hulla H. A study of replanted permanent teeth in different age groups. *Endod Dent Traumatol* 1998;14:274–8.
13. Trope M. Clinical management of the avulsed tooth: present strategies and future directions. *Dent Traumatol* 2002;18:1–11. Review.
14. Andreasen JO, Andreasen FM, Skeie A, Hjorting-Hansen E, Schwartz O. Effect of treatment delay upon pulp and periodontal healing of traumatic dental injuries – a review article. *Dent Traumatol* 2002;18:116–28.
15. Chappuis V, von Arx T. Replantation of 45 avulsed permanent teeth: a 1-year follow-up study. *Dent Traumatol* 2005;21:289–96.
16. Pohl Y, Filippi A, Kirschner H. Results after replantation of avulsed permanent teeth. I. Endodontic considerations. *Dental Traumatol* 2005;21:80–92.
17. Pohl Y, Filippi A, Kirschner H. Results after replantation of avulsed permanent teeth. II. Periodontal healing and the role of physiologic storage and antiresorptive-regenerative therapy. *Dent Traumatol* 2005;21:93–101.
18. Pohl Y, Wahl G, Filippi A, Kirschner H. Results after replantation of avulsed permanent teeth. III. Tooth loss and survival analysis. *Dental Traumatol* 2005;21:102–10.



19. Tzigkounakis V, Merglová V, Hecová H, Netolický J. Retrospective clinical study of 90 avulsed permanent teeth in 58 children. *Dent Traumatol* 2008;24:598–602.
20. Kargul B, Welbury R. An audit of the time to initial treatment in avulsion injuries. *Dent Traumatol* 2009;25:123–5.
21. Day P, Duggal M. Interventions for treating traumatised permanent front teeth: avulsed (knocked out) and replanted. *Cochrane Database Syst Rev* 2010;20:CD006542. Review.
22. Petrovic B, Marković D, Peric T, Blagojevic D. Factors related to treatment and outcomes of avulsed teeth. *Dent Traumatol* 2010;26:52–9.
23. Werder P, von Arx T, Chappuis V. Treatment outcome of 42 replanted permanent incisors with a median follow-up of 2.8 years. *Schweiz Monatsschr Zahnmed* 2011;12:312–20.
24. Andreasen JO, Andreasen FM, Bakland LK, Flores MT, Andersson L. *Traumatic dental injuries, a manual*, 3rd edn. Chichester, West Sussex: Wiley-Blackwell; 2011. p. 48–53.
25. Trope M. Avulsion of permanent teeth: theory to practice. *Dent Traumatol* 2011;27:281–94.
26. Andreasen JO. The effect of extra-alveolar period and storage media upon periodontal and pulpal healing after replantation of mature permanent incisors in monkeys. *Int J Oral Surg* 1981;10:43–51.
27. Andreasen JO. Periodontal healing after replantation of traumatically avulsed human teeth. Assessment by mobility testing and radiography. *Acta Odontol Scand* 1975;33:325–35.
28. Flores MT, Andersson L, Andreasen JO, Bakland LK, Malmgren B, Barnett F et al. Guidelines for the management of traumatic dental injuries. I. Fractures and Luxations of permanent teeth. *Dent Traumatol* 2007;23:66–71.
29. Flores MT, Andersson L, Andreasen JO, Bakland LK, Malmgren B, Barnett F et al. Guidelines for the management of traumatic dental injuries. II. Avulsion of permanent teeth. *Dent Traumatol* 2007;23:130–6.
30. Flores MT, Andersson L, Andreasen JO, Bakland LK, Malmgren B, Barnett F et al. Guidelines for the management of traumatic dental injuries. III. Primary teeth. *Dent Traumatol* 2007;23:196–202.
31. Stokes AN, Anderson HK, Cowan TM. Lay and professional knowledge of methods for emergency management of avulsed teeth. *Endod Dent Traumatol* 1992;8:160–2.
32. Hamilton FA, Hill FJ, Mackie IC. Investigation of lay knowledge of the management of avulsed permanent incisors. *Endod Dent Traumatol* 1997;13:19–23.
33. Chan AW, Wong TK, Cheung GS. Lay knowledge of physical education teachers about the emergency management of dental trauma in Hong Kong. *Dent Traumatol* 2001;17:77–85.
34. Glendor U. Has the education of professional caregivers and lay people in dental trauma care failed? *Dent Traumatol* 2009;25:12–8. Review.
35. Abu-Dawoud M, Al-Enezi B, Andersson L. Knowledge of emergency management of avulsed teeth among young physicians and dentists. *Dent Traumatol* 2007;23:348–55.
36. Al-Asfour A, Andersson L. The effect of a leaflet given to parents for first aid measures after tooth avulsion. *Dent Traumatol* 2008;24:515–21.
37. Al-Asfour A, Andersson L, Al-Jame Q. School teachers' knowledge of tooth avulsion and dental first aid before and after receiving information about avulsed teeth and replantation. *Dent Traumatol* 2008;24:43–9.
38. Andersson L, Al-Asfour A, Al-Jame Q. Knowledge of first aid measures of avulsion and replantation of teeth. An interview study of 221 Kuwaiti schoolchildren. *Dent Traumatol* 2006;22:57–65.
39. Al-Sane M, Bourisly N, Almulla T, Andersson L. Laypeople's preferred sources of health information on the emergency management of tooth avulsion. *Dent Traumatol* 2011;27:432–7.
40. Lieger O, Graf C, El-Maaytah M, Von Arx T. Impact of educational posters on the lay knowledge of school teachers regarding emergency management of dental injuries. *Dent Traumatol* 2009;25:406–12.
41. McIntyre JD, Lee JY, Trope M, Vann WF Jr. Effectiveness of dental traumaducation for elementary school staff. *Dent Traumatol* 2008;24:146–50.
42. Feldens EG, Feldens CA, Kramer PF, da Silva KG, Munari CC, Brei VA. Understanding school teacher's knowledge regarding dental trauma: a basis for future interventions. *Dent Traumatol* 2010;26:158–63.
43. Levin L, Jeffet U, Zadik Y. The effect of short dental trauma lecture on knowledge of high-risk population: an intervention study of 336 young adults. *Dent Traumatol* 2010;26:86–9.
44. Blomlöf L, Andersson L, Lindsog S, Hedström K-G, Hammarström L. Periodontal healing of replanted monkey teeth prevented from drying. *Acta Odontol Scand* 1983;41:117–23.
45. Blomlöf L, Lindsog S, Andersson L, Hedström K-G, Hammarström L. Storage of experimentally avulsed teeth in milk prior to replantation. *J Dent Res* 1983;62:912–6.
46. Andreasen JO, Kristersson L. The effect of limited drying or removal of the periodontal ligament: periodontal healing after replantation of mature permanent incisors in monkeys. *Acta Odontol Scand* 1981;39:1–13.
47. Hiltz J, Trope M. Vitality of human lip fibroblasts in milk, Hanks Balanced Salt Solution and Viaspan storage media. *Endod Dent Traumatol* 1991;7:69–72.
48. Trope M, Friedman S. Periodontal healing of replanted dog teeth stored in Viaspan, milk and Hanks Balanced Salt Solution. *Endod Dent Traumatol* 1992;8:183–8.
49. Filippi C, Kirschner H, Filippi A, Pohl Y. Practicability of a tooth rescue concept – the use of a tooth rescue box. *Dent Traumatol* 2008;24:422–9.
50. de Souza BD, Bortoluzzi EA, da Silveira Teixeira C, Felipe WT, Simões CM, Felipe MC. Effect of HBSS storage time on human periodontal ligament fibroblast viability. *Dent Traumatol* 2010;26:481–3.
51. Hammarström L, Pierce A, Blomlöf L, Feiglin B, Lindsog S. Tooth avulsion and replantation: a review. *Endod Dent Traumatol* 1986;2:1–9.
52. Andersson L, Blomlöf L, Lindsog S, Feiglin B, Hammarström L. Tooth ankylosis. Clinical, radiographic and histological assessments. *Int J Oral Surg* 1984;13:423–31.
53. American Academy of Pediatrics, Committee on Pediatrics Emergency Medicine and Committee on Bioethic. Consent for emergency medical services for children and adolescents. *Pediatrics* 2011;128:427–33.
54. American Academy of Pediatrics, Council on Community Paediatrics and Committee on Native American Child Health. Health equity and children's rights. *Pediatrics* 2010;125:838–49.
55. World report on child injury prevention. World Health Organization, 2008. Chapter 7. p. 145–55. [http://whqlibdoc.who.int/publications/2008/9789241563574\\_eng.pdf](http://whqlibdoc.who.int/publications/2008/9789241563574_eng.pdf) [accessed on 6 November 2011].
56. Kling M, Cvek M, Mejäre I. Rate and predictability of pulp revascularization in therapeutically replanted permanent incisors. *Endod Dent Traumatol* 1986;2:83–9.
57. Andersson L, Malmgren B. The problem of dentoalveolar ankylosis and subsequent replacement resorption in the growing patient. *Aust Endod J* 1999;25:57–61.
58. Filippi A, Pohl Y, Von Arx T. Decoronation of an ankylosed tooth for preservation of alveolar bone prior to implant placement. *Dent Traumatol* 2001;17:93–5.
59. Cohenca N, Stabholz A. Decoronation – a conservative method to treat ankylosed teeth for preservation of alveolar ridge prior to permanent prosthetic reconstruction: literature review and case presentation. *Dent Traumatol* 2007;23:87–94.
60. Coccia CT. A clinical investigation of root resorption rates in reimplanted young permanent incisors: a five-year study. *J Endod* 1980;6:413–20.
61. Esper HR, Panzarini SR, Poi WR, Sonoda CK, Casatti CA. Mechanical removal of necrotic periodontal ligament by either Robinson bristle brush with pumice or scalpel blade. Histomorphometric analysis and scanning electron microscopy. *Dent Traumatol* 2007;23:333–9.

62. Lindskog S, Blomlöf L, Hammarström L. Cellular colonization of denuded root surfaces in vivo: cell morphology in dentin resorption and cementum repair. *J Clin Periodontol* 1987;14:390–5.
63. Panzarini SR, Gulinielli JL, Poi WR, Sonoda CK, Pedrini D, Brandini DA. Treatment of root surface in delayed tooth replantation: a review of literature. *Dent Traumatol* 2008;24:277–82. Review.
64. Mariano ER, Watson D, Loland VJ, Chu LF, Cheng GS, Mehta SH et al. Bilateral infraorbital nerve blocks decrease postoperative pain but do not reduce time to discharge following outpatient nasal surgery. *Can J Anaesth* 2009;56:584–9.
65. Barnett P. Alternatives to sedation for painful procedures. *Pediatr Emerg Care* 2009;25:415–9; quiz 420–2.
66. Karkut B, Reader A, Drum M, Nusstein J, Beck M. A comparison of the local anesthetic efficacy of the extraoral versus the intraoral infraorbital nerve block. *J Am Dent Assoc* 2010;141:185–92.
67. Andreasen JO, Storgaard Jensen S, Sae-Lim V. The role of antibiotics in preventing healing complications after traumatic dental injuries: a literature review. *Endod Topics* 2006;14:80–92.
68. Bryson EC, Levin L, Banchs F, Trope M. Effect of minocycline on healing of replanted dog teeth after extended dry times. *Dental Traumatol* 2003;19:90–5.
69. Chen H, Teixeira FB, Ritter AL, Levin L, Trope M. The effect of intracanal anti-inflammatory medicaments on external root resorption of replanted dog teeth after extended extra-oral dry time. *Dent Traumatol* 2008;24:74–8.
70. Cvek M, Cleaton-Jones P, Austin J, Lownie J, Kling M, Fatti P. Effect of topical application of doxycycline on pulp revascularization and periodontal healing in reimplanted monkey incisors. *Endod Dent Traumatol* 1990;6:170–6.
71. Hammarström L, Blomlöf L, Feiglin B, Andersson L, Lindskog S. Replantation of teeth and antibiotic treatment. *Endod Dent Traumatol* 1986;2:51–7.
72. Björvatn K, Selvig KA, Klinge B. Effect of tetracycline and SnF<sub>2</sub> on root resorption in replanted incisors in dogs. *Scand J Dent Res* 1989;97:477–82.
73. Ritter AL, Ritter AV, Murrah V, Sigurdsson A, Trope M. Pulp revascularization of replanted immature dog teeth after treatment with minocycline and doxycycline assessed by laser Doppler flowmetry, radiography, and histology. *Dent Traumatol* 2004;20:75–84.
74. Sae-Lim V, Wang C-Y, Choi G-W, Trope M. The effect of systemic tetracycline on resorption of dried replanted dogs' teeth. *Endod Dent Traumatol* 1998;14:127–32.
75. Sae-Lim V, Wang C-Y, Trope M. Effect of systemic tetracycline and amoxicillin on inflammatory root resorption of replanted dogs' teeth. *Endod Dent Traumatol* 1998;14:216–20.
76. Yanpiset K, Trope M. Pulp revascularization of replanted immature dog teeth after different treatment methods. *Endod Dent Traumatol* 2000;16:211–7.
77. Oikarinen K. Tooth Splinting – a review of the literature and consideration of the versatility of a wire-composite splint. *Endod Dent Traumatol* 1990;6:237–50.
78. Andreasen JO. The effect of splinting upon periodontal healing after replantation of permanent incisors in monkeys. *Acta Odontol Scand* 1975;33:313–23.
79. Andersson L, Lindskog S, Blomlöf L, Hedström K-G, Hammarström L. Effect of masticatory stimulation on dentoalveolar ankylosis after experimental tooth replantation. *Endod Dent Traumatol* 1985;1:13–6.
80. Berthold C, Thaler A, Petschelt A. Rigidity of commonly used dental trauma splints. *Dent Traumatol* 2009;25:248–55.
81. Hinckfuss S, Messer LB. Splinting duration and periodontal outcomes for replanted avulsed teeth, a systematic review. *Dent Traumatol* 2009;25:150–7.
82. Kahler B, Heithersay GS. An evidence-based appraisal of splinting luxated, avulsed and root-fractured teeth. *Dent Traumatol* 2008;24:2–10. Review.
83. VonArx T, Fillipi A, Lussi A. Comparison of a new dental trauma splint device (TTS) with three commonly used splinting techniques. *Dent Traumatol* 2001;17:266–74.
84. Abbott PV, Heithersay GS, Hume WR. Release and diffusion through human tooth roots in vitro of corticosteroid and tetracycline trace molecules from Ledermix paste. *Endod Dent Traumatol* 1988;4:55–62.
85. Bryson EC, Levin L, Banchs F, Abbott PV, Trope M. Effect of immediate intracanal placement of Ledermix Paste(R) on healing of replanted dog teeth after extended dry times. *Dent Traumatol* 2002;18:316–21.
86. Abbott PV, Hume WR, Heithersay GS. Effects of combining Ledermix and calcium hydroxide pastes on the diffusion of corticosteroid and tetracycline through human roots in vitro. *Endod Dent Traumatol* 1989;5:188–92.
87. Andreasen JO. The effect of pulp extirpation or root canal treatment of periodontal healing after replantation of permanent incisors in monkeys. *J Endod* 1981;7:245–52.
88. Day PF, Gregg TA, Ashley P, Welbury RR, Cole BO, High AS et al. Periodontal healing following avulsion and replantation of teeth: a multi-centre randomized controlled trial to compare two root canal medicaments. *Dent Traumatol* 2012;28:55–64.
89. Day PF, Duggal MS, High AS, Robertson A, Gregg TA, Ashley PF et al. Discoloration of teeth after avulsion and replantation: results from a multicenter randomized controlled trial. *J Endod* 2011;37:1052–7.
90. Wong KS, Sae-Lim V. The effect of intracanal Ledermix on root resorption of delayed-replanted monkey teeth. *Dent Traumatol* 2002;18:309–15.
91. Kirakozova A, Teixeira FB, Curran AE, Gu F, Tawil PZ, Trope M. Effect of intracanal corticosteroids on healing of replanted dog teeth after extended dry times. *J Endod* 2009;35:663–7.
92. Pierce A, Lindskog S. The effect of an antibiotic corticosteroid combination on inflammatory root resorption. *J Endod* 1988;14:459–64.
93. Stewart CJ, Elledge RO, Kinirons MJ, Welbury RR. Factors affecting the timing of pulp extirpation in a sample of 66 replanted avulsed teeth in children and adolescents. *Dent Traumatol* 2008;24:625–7.
94. Kinirons MJ, Gregg TA, Welbury RR, Cole BO. Variations in the presenting and treatment features in reimplanted permanent incisors in children and their effect on the prevalence of root resorption. *Br Dent J* 2000;189:263–6.
95. Malmgren B, Malmgren O, Andreasen JO. Alveolar bone development after decoronation of ankylosed teeth. *Endod Topics* 2006;14:35–40.