

Influence of suturing on wound healing

RINO BURKHARDT & NIKLAUS P. LANG

Proper closure and stabilization of wound margins in their desired position are critical events that influence the success of any surgical outcome. Numerous unique methods and materials have been proposed to achieve successful wound closure in various surgical disciplines. However, there are inherent challenges in periodontal plastic and implant surgery, and these may complicate the procedures. Whilst working in the oral cavity, clinicians are confronted with a variety of anatomical structures, such as hard and soft tissues adjacent to each other. Moreover, access to the relevant structures is often limited, and the patient, with his/her specific tongue mobility and swallowing pattern, may additionally complicate operator maneuverability in an area that is already characterized by restricted access. Furthermore, flap stability and healing outcomes may be hampered during the postoperative phase because the oral cavity is an aqueous environment and the formation of biofilm takes place on the nonshedding surfaces in this environment. Consequently, bacterial colonization may jeopardize uneventful healing. Additionally, the negative effect of the mechanical influences of continuous masticatory and other functions of the dentition on wound closure should not be underestimated (28). Moreover, environmental and behavioral aspects, such as cigarette smoking and poor oral hygiene, may have a greatly negative impact on the optimal outcome of the surgical procedure (42).

Denuded bone and exposed root surfaces caused by the surgical intervention must generally be covered by the soft tissue flap if optimal outcomes are to be achieved. In addition, flap margins created by surgical incisions are preferably approximated and closed to allow healing by primary intention. This, in turn, may minimize postoperative bone resorption and further attachment loss at teeth, providing that a relatively clean and plaque-free situation is maintained. Moreover, mucoperiosteal and/or mucosal

flaps positioned to cover large periodontal or peri-implant defects require careful tissue management and adaptation owing to the fact that the wound comprises several interfaces of tissue that differ fundamentally in composition. In one instance, the connective tissue surface of the flap opposes another vascularized wound surface and includes both mucosal connective tissue and alveolar bone. In other instances, an avascular surface, such as cementum, enamel, dentine or bone, or alloplastic surfaces, such as titanium or ceramics, oppose the vascularized connective tissue wound.

Wound healing depends primarily on early formation and organization of the blood clot and the establishment of an attachment of the clot that is resistant to mechanical forces acting on the flap and opposing surfaces participating in the wound closure (48). Impaired clot adhesion may weaken the tensile strength of the wound during the early healing events and leave the root surface–gingival flap interface susceptible to tearing compared with tensile forces arising physiologically on wound margins (47). Such rupture between the flap and participating wound surfaces may be the result of naturally occurring tensile forces or a developing tissue edema if postoperative flap stability cannot be guaranteed.

Tensile forces vary depending upon the stability of the blood clot and subsequently on the biochemical and mechanical properties of the wound bed (46). Hence, healing in periodontal and peri-implant defects following flap surgery are conceptually more complex processes than is wound healing in most other sites in the body. It is evident that suturing receives a higher degree of attention in situations where mechanical stability of the flap is required. The present article focuses on the biological aspects of the utilization of sutures in attempting primary wound closure and the role of suturing in providing wound stabilization.

Suturing materials

A discussion of the choice of appropriate suturing material and the techniques applied appears to be a prerequisite for understanding wound physiology. The most popular technique for wound closure is the application of sutures, which are used to stabilize the wound margins effectively, and to a high degree, in order to ensure proper wound closure for a defined period of time without impinging on the physiological aspects of wound healing (6). As a consequence, suturing is often the most technique-sensitive and time-consuming part of a surgical procedure, and hence some clinicians have proposed that sutures should be eliminated and replaced with other methods of wound closure (18). Such methods include the application of surgical clamps and adhesive agents for securing the wound margins. Whilst the former are not suitable for routine surgery in the oral cavity owing to the high cost and the failure to influence the closing forces (25), the latter may be applied occasionally. Cyanoacrylate tissue adhesives, as alternatives to the placement of sutures, have been investigated in a variety of health-care settings (17, 43) and their beneficial effects have been proven for closure of superficial skin lacerations under tension (32).

Although favorable outcomes have been reported for the use of tissue adhesives following periodontal flap surgery (11, 13, 19, 20, 32), there are also inherent disadvantages. The bacteriostatic and hemostatic effects of the product, as well as the reduced treatment time (12), failed to compensate for the negative properties, such as difficulties in application, prolonged healing times (12) and insufficient adherence of mobile wound margins (1). In conclusion, cyanoacrylate tissue adhesives cannot provide a stable adaptation of wound margins over a predetermined period of time and hence are not suitable for wound closure in periodontal plastic surgery.

Development of natural suture materials

During the 20th century, threads of the natural products silk, cotton and linen were predominantly used as suture materials was employed (16). Braided silk is characterized by high resistance to tearing forces. However, in the human body, silk sutures may lead to foreign body reactions. Because of their straightforward handling properties and the ability to apply a silk suture at the appropriate tension, this material is still used despite its limited tissue-compatibility features. However, it should be noted

that silk sutures are also prone to colonization by biofilms. Hence, silk should not be applied for prolonged periods of time.

Catgut is manufactured from the submucosa of the intestine of sheep or cattle. Within 6–14 days after clinical use catgut loses its consistency owing to enzymatic resorption (26). Treatment of the catgut material with chemical agents did not prevent resorption. In soft tissues the material may generate inflammatory reactions with marked cellular infiltrations. For this reason, catgut is no longer utilized in periodontal surgery (38).

Synthetic suture materials

In current periodontal surgical practice, synthetic threads are predominantly employed. According to their behavior in tissue, they are divided into two categories: resorbable materials and nonresorbable materials (22). Within these categories the materials can be further divided into monofilament and polyfilament threads. As polyfilament threads are characterized by a high capillarity action, thus promoting the risk of infection by bacterial contamination of the thread, monofilament threads are generally preferred (30). Pseudomonofilaments are coated polyfilament threads, which have the aim of reducing mechanical tissue trauma. However, during suturing, the coating breaks, and the properties of the pseudomonofilament threads are then the same as those of the polyfilament threads (23). Moreover, fragments of the coating may invade the surrounding soft tissues and elicit a foreign-body reaction (9).

The advantages of synthetic sutures are their stable physical properties and, once placed *in situ*, their biocompatibility. Synthetic suture materials are composed of polymerization products of amines and acids (polyamides), unsaturated carbohydrates (polyolefins), alcohols and acids (polyesters). Glycolic acid is both an alcohol and an acid, which explains why it is categorized under the polyesters.

Nonresorbable synthetic threads

A material commonly used to produce fine monofilament threads (of 0.01–0.1 mm diameter) that yields adequate tissue properties is polyamide. Tissue reactions are extremely rare, occurring only after errors in the polymerization process. As an additional choice, polyolefins are inert materials that undergo no hydrolytic degradation in oral tissues (37). Materials with excellent tissue properties are polypropylene and its newest development, polyhexafluoropropylene. After

suturing, these threads become encapsulated in connective tissue and are stable for a long period of time.

Suturing threads are classified according to their thickness (Table 1). It should be noted that, depending on the manufacturers, either the European or the American nomenclature will apply. European manufacturers follow a metric classification system, whereas American manufacturers follow an arbitrary classification system. European products will comply strictly with the European system and reveal the thickness of the thread. However, American products do not follow the classification according to the diameter of the threads. Monofilament threads 5-0 or thicker are relatively stiff and hence may impact negatively upon patient comfort. A substance with similar biological, but improved handling, properties is expanded polytetrafluorethylene (Teflon[®]). Owing to their porous surface structure, the use of monofilament threads in the bacterially contaminated oral cavity is recommended with caution.

Resorbable synthetic threads

Owing to their stable physical properties before use and the controlled degradation thereafter, resorbable synthetic threads are advantageous (16). The materials in this category belong to the polyesters, the polyamides or the polyolefins. Polyester threads are mechanically stable and lose their firmness at different, but constant times during use by hydration into alcohol and acid. Moreover, polyester threads are mechanically stable and lose their firmness at different, but constant, times during use. A 50% reduction in breaking resistance can be expected after 2–3 weeks for both polyglycolic acid and polyglactin threads, after 4 weeks for polyglyconate and after 5 weeks for polydioxanone threads. The capillary effect depends on the material. It is limited for polyester threads and minimal for polyglactin sutures (2).

Table 1. Classification of suturing materials

European pharmacopoe		American pharmacopoe		
All suturing materials, resorbable and nonresorbable	Diameter of threads	All suturing materials, except collagen	Diameter of threads	Collagenous suturing materials
Metric no.	Scale (mm)	USP no.	Scale (mm)	USP no.
0.1	0.010–0.019	11-0	0.010–0.019	
0.2	0.020–0.029	10-0	0.020–0.029	
0.3	0.030–0.039	9-0	0.030–0.039	
0.4	0.040–0.049	8-0	0.040–0.049	
0.5	0.050–0.069	7-0	0.050–0.069	
0.7	0.070–0.099	6-0	0.070–0.099	7-0
1	0.100–0.149	5-0	0.100–0.149	6-0
1.5	0.150–0.199	4-0	0.150–0.199	5-0
2	0.200–0.249	3-0	0.200–0.249	4-0
3	0.300–0.349	2-0	0.300–0.349	3-0
3.5	0.350–0.399	0	0.350–0.399	2-0
4	0.400–0.499	1	0.400–0.499	0
5	0.500–0.599	2	0.500–0.599	1
6	0.600–0.699	3 + 4	0.600–0.699	2
7	0.700–0.799	5	0.700–0.799	3
8	0.800–0.899	6	0.800–0.899	4
9	0.900–0.999	7	0.900–0.999	5
10	1.000–1.099	8	1.000–1.099	6

Characteristics of the needles

The needles comprise a swage, the body and a tip. They differ in composition materials, length, size, tip configuration, body diameter and the nature of connection between the needle and the thread. In atraumatic sutures the thread is firmly connected to the needle through a press-fit swage or stuck in a laser-drilled hole. There are no differences, with respect to stability, in the two attachment modalities (45).

The body of the needle is preferably flattened to prevent twisting or rotation in the needle holder. The needle tips differ widely depending on the purpose for which they are used. Tips of cutting needles are appropriate for coarse tissues or atraumatic penetrations. In order to minimize tissue trauma, the sharpest needle, namely reverse cutting needles with precision tips or spatula needles with micro tips, are recommended (41).

The shape of the needle may be straight or bent to various degrees. For periodontal purposes, the 3/8" circle needle generally ensures optimal results. There is a wide range of variation in needle length, which is measured along the needle curvature from the tip to the proximal end of the needle lock. For interdental sutures in the posterior area, needle lengths of 13–15 mm are appropriate. The same procedure in the anterior aspect requires needle lengths of 10–12 mm. For closing buccal-releasing incisions, needle lengths of 5–8 mm are adequate.

To guarantee perpendicular penetration through the soft tissues that prevents tearing, an asymptotic curved needle is advantageous in areas where narrow penetrations are required (e.g. the base of the papillae). To fulfil these prerequisites for optimal wound closure, at least two different sutures are used in most surgical interventions.

Recommendation for appropriate suturing

In Table 2, ideal needle–thread combinations (nonresorbable) for use in periodontal and peri-implant surgical procedures are indicated.

Tissue reactions and trauma from suturing

As a result of the penetration trauma, the tissue reaction after suturing peaks at the third postoperative day (39). Both resorbable and nonresorbable threads result in comparable penetration trauma (35). Histo-

logically, the early response is characterized by three zones of alterations (39): (i) a high level of cell exudate in the immediate vicinity of the entry to the stitch canal, followed by (ii) a concentric area harboring damaged cells as well as intact tissue fragments and (iii) a wide zone of inflammatory cells in the surrounding connective tissues.

If a resorbable suture is left *in situ* for more than 2 weeks after wound closure, an acute inflammatory reaction still exists. This phenomenon is caused by entry of bacteria into the stitch canal and penetration into the polyfilament suture material (9, 39). *In-vivo* studies have confirmed increased risks for bacterial migration along the thread in the humid and bacterially loaded oral cavity (34, 35).

Experimental and clinical data indicate that most wound infections begin around suture material left within the wound (10, 44). Polyfilament threads additionally facilitate bacterial migration, and bacteria can also penetrate the inner compartment of the thread that impairs the immunological response of the host (3, 15). This is the only reason why monofilament, nonresorbable sutures should be preferred and removed at the earliest biologically acceptable time (14). The infectious potential may further be reduced by applying anti-infective therapy based on daily irrigation or topical application of chlorhexidine (21). Another promising option to reduce the migration of bacteria along the suture is to coat it with a bacteriostatic substance. Vicryl® Plus (Ethicon, Norderstedt, Germany) is a resorbable suture material coated with Triclosan® that inhibits bacterial growth for up to 6 days by damaging the cell membranes (37).

In an angiographic study on dogs (24), the vascular events following mucoperiosteal flap elevation were studied in relation to two different suturing techniques. After flap adaptation, primary wound closure was achieved by either horizontal mattress suturing or interrupted single suturing. The flaps were reflected in the mandibular posterior regions on both buccal and lingual aspects and were divided into three interproximal and two mid-buccal sites for analysis of the extent of the intercapillary and vascular diffusion. It was realized that the sole act of flap elevation initiated substantial and significant vascular trauma. Significant reduction in flap circulation in relation to the presurgical baseline situation lasted for at least 3 days in the mid-buccal sites but persisted for 7 days at the interproximal sites. No significant differences in the vascular changes could be detected between the two suturing techniques. However, both suturing techniques appeared to have exercised a local negative influence on the circulation until they were removed.

Table 2. Ideal needle–thread combinations (nonresorbable) for use in periodontal and peri-implant surgery

Indications	Suture strength	Needle characteristics	Thread materials	Product name
Buccal releasing incisions	7-0	³ / ₈ curvature needle Cutting needle with precision tip Needle length 7.6 mm	Polypropylene	Prolene [®] Mopylen [®]
	7-0	Asymptotic curved needle Cutting needle tip, round body Needle length 8.9 mm	Polypropylene	Prolene [®] Mopylen [®]
	9-0	³ / ₈ curvature needle Spatula needle Needle length 5.2 mm	Polyamide	Ethilon [®] Resolon [®] Nylon
Interdental sutures				
Front area	6-0	³ / ₈ curvature needle Cutting needle with precision tip Needle length 11.2 mm	Polypropylene	Prolene [®] Mopylen [®]
	7-0	³ / ₈ curvature needle Cutting needle with precision tip Needle length 11.2 mm	Polyamide	Ethilon [®] Resolon [®] Nylon
Premolar area	6-0	³ / ₈ curvature needle Cutting needle with precision tip Needle length 12.9 mm	Polyamide	Ethilon [®] Resolon [®] Nylon
	6-0	³ / ₈ curvature needle Cutting needle with precision tip Needle length 12.9 mm	Polypropylene	Prolene [®] Mopylen [®]
Molar area	6-0	³ / ₈ curvature needle Cutting needle with precision tip Needle length 16.2 mm	Polyamide	Ethilon [®] Resolon [®] Nylon
Crestal incisions	7-0	³ / ₈ curvature needle Cutting needle with precision tip Needle length 11.2 mm	Polyamide	Ethilon [®] Resolon [®] Nylon
	6-0	³ / ₈ curvature needle Cutting needle with precision tip Needle length 12.9 mm	Polypropylene	Prolene [®] Mopylen [®]
Papilla base incisions	7-0	Asymptotic curved needle Cutting needle tip, round body Needle length 8.9 mm	Polypropylene	Prolene [®] Mopylen [®]
	9-0	¹ / ₂ curvature needle Cutting needle with micro tip Needle length 8.0 mm	Polyamide	Ethilon [®] Resolon [®] Nylon

This, in turn, means that suturing may severely compromise the microcirculation of flaps and hence jeopardize optimal physiological wound healing.

The influence of the suturing technique on the vascularization of gingival wounds has been explored in a clinical prospective cohort in which connective tissue grafts were covered by a double pedicle papilla flap in order to cover denuded root surfaces (5). In 10 patients with bilateral Miller Class I and II maxillary canine recessions (27), coverage of the root surfaces was performed either by macrosurgical or microsurgical approaches. The latter included the utilization of a surgical microscope, fine microsurgical instruments

and ophthalmic blades as well as the application of 7-0 and 9-0 polypropylene threads, whilst the former served as a control using a conventional approach without additional magnification and using 4-0 sutures. The angiographic results of the microsurgical approach yielded a significant improvement in vascularization after 3 and 7 days compared with the controls (Fig. 1). Moreover, the average percentage of root recession coverage 1 year postoperatively was 98% for the microsurgical approach and 89.9% for the macrosurgical approach, indicating a significantly improved surgical outcome as a result of a superior early vascularization of the flaps (5) (Fig. 2).

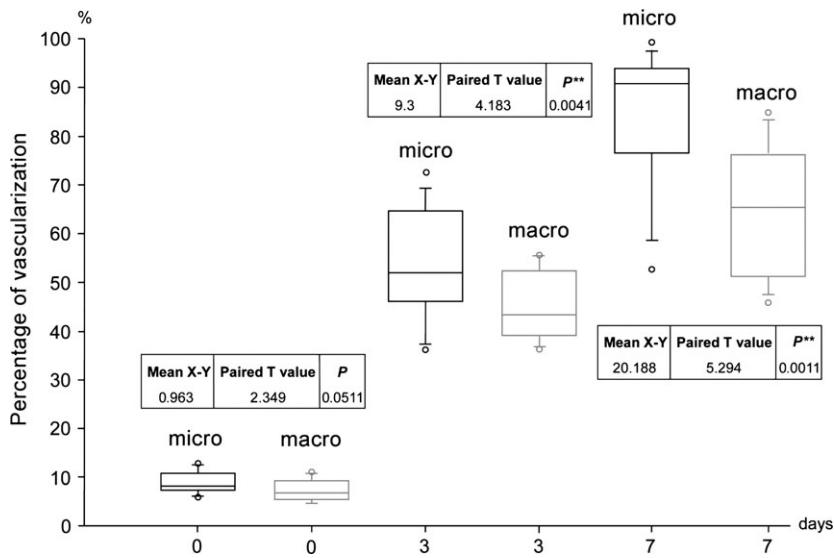


Fig. 1. Angiographic evaluation illustrated by box-and-whisker plots. Outliers are shown as °. * $P < 0.05$, ** $P < 0.01$. (Courtesy of ref. 40.). Micro: 7-0 and 9-0 suture materials, microsurgical instruments and use of a surgical microscope with 15 \times magnification. Macro: 4-0 polyfilament suture materials, conventional surgical instruments, no magnification

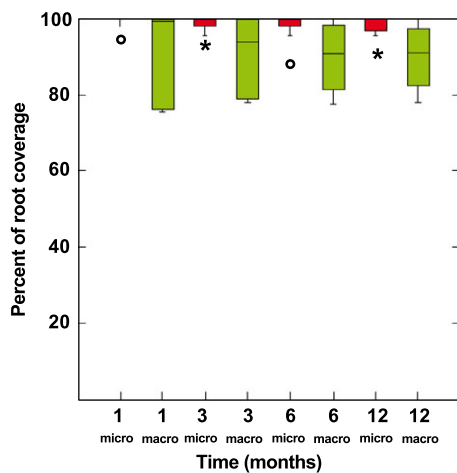


Fig. 2. Root recession coverage illustrated by box-and-whisker plots. * and ° indicate outliers outside and far outside. (Courtesy of ref. 40.). Micro: 7-0 and 9-0 suture materials, microsurgical instruments and use of a surgical microscope with 15 \times magnification. Macro: 4-0 polyfilament suture materials, conventional surgical instruments, no magnification

Based on the studies discussed, it is evident that prolonged retention time of sutures may have negative effects on the surgical outcome. This is a result of both the potential infection of the threads with bacteria as well as the mechanical trauma induced by tissue edema.

Role of wound stability

Blood clot formation appears to be a prerequisite for closure of every wound. In reconstructive periodontal surgery, adhesion of the blood clot to a denuded root surface is the key feature to initiate the regenerative

process, leading to new connective tissue attachment mediated by the formation of new cementum. In an animal experiment, initial blood clot adhesion was chemically hampered by the application of heparin, whilst contralateral control defects were treated with saline. The heparin-treated teeth exhibited 50% connective tissue repair to the root surface after 4 weeks, whereas the controls displayed 95% repair. Heparin treatment of the root surfaces jeopardized blood clot adhesion and hence connective tissue repair of the periodontal defects was severely delayed (49). As fibrin clot adhesion was disturbed chemically by the application of heparin, it must be assumed that mechanical displacement of a flap on a wound surface may result in similar disturbances of fibrin clot adhesion. Hence, the stabilization of the soft tissues covering the wound area with appropriate suturing appears to be a key prerequisite for optimal surgical outcomes.

The influence of residual tension within flaps before suturing was assessed in a human randomized prospective study in patients treated for Miller Class I (49) maxillary recessions (33). On one side, coronally advanced flaps were replaced and sutured under regular residual tension. On the control side, the flaps were further relaxed before suturing. Although the residual tension was 6.5 g on the test sides, it was only 0.4 g on the control sides. After 3 months of healing, the mean root coverage at test sites was 78%, with complete root coverage in 18% of the subjects. However, the mean root coverage on the control side was 87% with 45% of the subjects yielding complete coverage. Although the difference in residual flap tension was minimal (ca. 6 g), the influence on the reduction of recession was significant, again indicating the necessity of a tension-free flap closure when applying appropriate suturing for optimal outcomes (33).

The forces acting on the flap in the previous study were rather small in size; however, wound strength at the dentine–connective tissue and the bone–connective tissue interfaces has been studied in dogs following full-thickness flap surgery (46). Tensile forces were applied using a microprocessor gauge at 1, 2, 3, 7, 10, 14, 21 and 28 days postoperatively. The mean tensile strength was markedly weaker at the dentine–flap interface compared with the bone–flap interface. After 1 week, the value was 1.82N for the former and 5.08N for the latter. Such differences were observed throughout the whole experimental period. The efforts to stabilize periodontal flaps at the soft/hard tissue interfaces by applying appropriate suturing has herewith been confirmed, especially during the first week following the intervention.

Although most of the models discussed dealt with interfaces in recession coverage, one study investi-

gated the role of flap tension in primary wound closure in humans (8). In that study, 60 patients scheduled for single implant installation were recruited. Before suturing, the tensile forces of the flap were recorded with an electronic tension-measuring device. After 1 week the wounds were inspected with regard to complete closure. Whilst flaps with a minimal initial tension of 0.01–0.1N resulted in only a few (10%) wound dehiscences, flaps with higher closing forces (>0.1N) yielded significantly increased percentages of wound dehiscence (>40%) (Fig. 3). This study also revealed that flaps with a thickness of >1 mm demonstrated significantly lower proportions of flap dehiscence at higher closing forces (>15 g) compared with thinner flaps (≤1 mm) (Fig. 4A, B). The results of this study (8) indicate the necessity to control closing forces at the wound margins. In order to minimize tissue trauma, sutures with

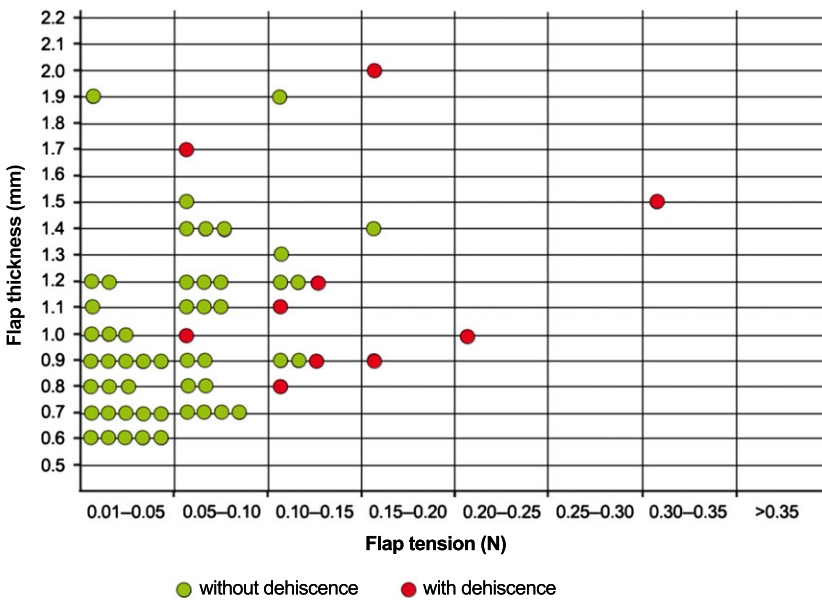


Fig. 3. Distribution pattern of sites with and without dehiscence related to flap thickness and applied closing forces. (Courtesy of ref. 43.)

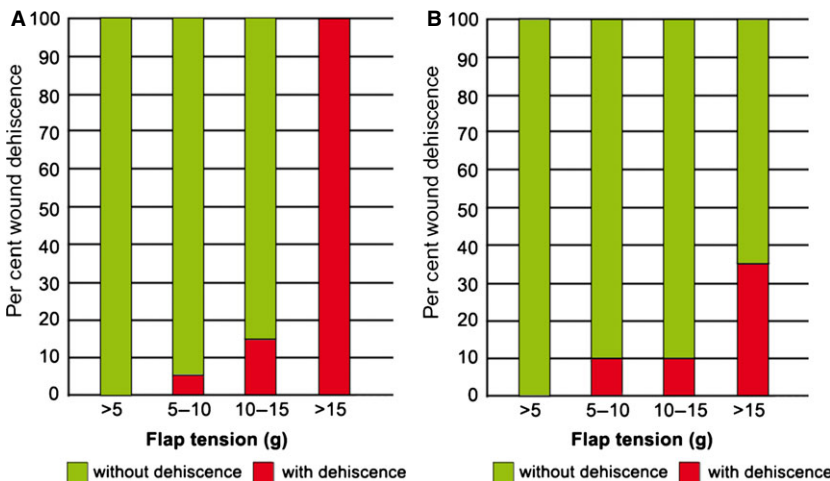


Fig. 4. Percentages of wound dehiscences of thin flaps (≤1 mm) (A) and of thick flaps (>1 mm) (B) according to the applied closing forces. (Courtesy of ref. 43.)

a finer diameter may be helpful owing to the fact that thinner sutures (6-0 and 7-0) lead to thread breakage rather than to tissue tear and breakage (7).

In order to improve the stability of the wound further, it should be realized that completely passive flap adaptation does not necessarily lead to the best healing outcomes. Wounds in rat skin with early suture removal on the fourth postoperative day showed significantly increased breaking strength at 1 week compared with those in which the sutures had been removed after 7 days (31). A relationship between wound-closing tension and tensile strength in rat skin was demonstrated using linear regression analysis (29): increasing closing tension may lead to higher tensile strength and consequently to a stronger scar with increased collagen deposition. In another rat study (4), scar width also increased with closing tension, and wounds closed under tension were wider and considered inferior. Hence, both factors – scar width and breaking strength – have to be taken into account when evaluating wound stability. Depending upon the location of the surgery, a strong wound or a narrow scar may be preferred, respectively.

Suturing techniques for optimal wound closure

The primary objective of suturing is to position and secure surgical flaps to promote optimal healing. When used properly, surgical sutures should hold flap edges in apposition until the wound has healed or has enough strength to withstand normal functional stresses. To fulfil this requirement, firm anchorage points must be selected in order to maintain the stability of the surgical suture over time.

In the oral cavity, four main anchoring structures are present. The most secure and easiest to use are teeth and immobile implants, which offer a firm anchor for sling or suspensory sutures. The second most reliable anchor is the masticatory mucosa, which lacks elastic fibers and is firmly affixed to bone via the periosteum. This tissue is especially important in securing vertical-releasing incisions and in areas adjacent to mucosal grafts (28). The periosteum, either bound down or elevated, can also be useful for positioning movable soft tissues. The connective tissue of the vestibule, owing to its mobility, is the least

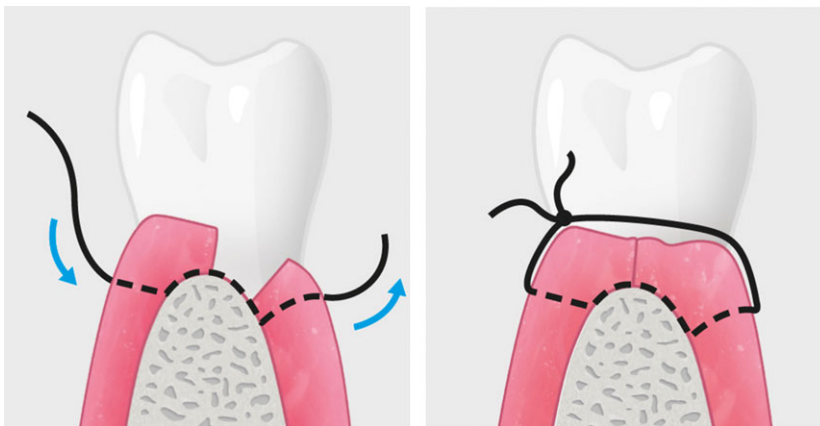


Fig. 5. Interrupted suture (simple loop), the most commonly used technique in periodontal surgery.

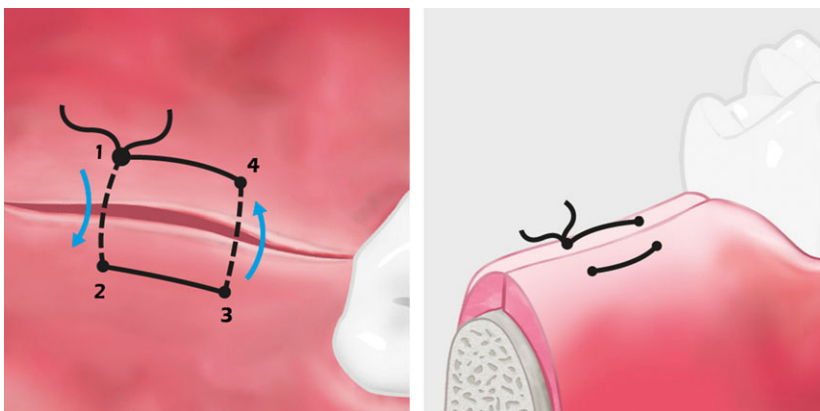


Fig. 6. Horizontal everting mattress suture that keeps the epithelium away from underlying structures and increases the contact area of adjacent wound surfaces.

secure anchoring point in the oral cavity. The availability and selection of appropriate anchorage points are key issues in deciding on the flap design and must be determined before the first incision.

One main feature of periodontal and peri-implant plastic surgery suturing is the use of various types and combinations of sutures. The interrupted simple loop is the most commonly used technique in periodontal plastic surgery (Fig. 5) and is routinely used to affix tension-free, mobile surgical flaps. Clinical examples are wound closure in edentulous ridge areas and the fixation of vertical releasing incisions. Another suturing technique, which is a variation of the interrupted suture, is the mattress suturing technique (40). This technique is usually used in areas where a tension-free flap closure cannot be accom-

plished or pressure has to be applied to the covering flap. Mattress sutures are generally used to resist muscle pull, everted (Fig. 6) or inverted (Fig. 7) wound edges and adapt the tissue flaps tightly to the underlying structures (e.g. bone graft, soft tissue graft, alveolar ridge or oral implant). Variations of the mattress suturing technique are referred to as the horizontal (Figs 6 and 7), the vertical (Fig. 8), the vertical sling and combined (inverting and everting) mattress sutures.

Another variation of the interrupted suturing technique is called a continuous suture, which can be used to attach two surgical flap edges or to secure multiple interproximal papillae of one flap independently of another flap. The disadvantages of using any continuous suture far outweigh the advantages of

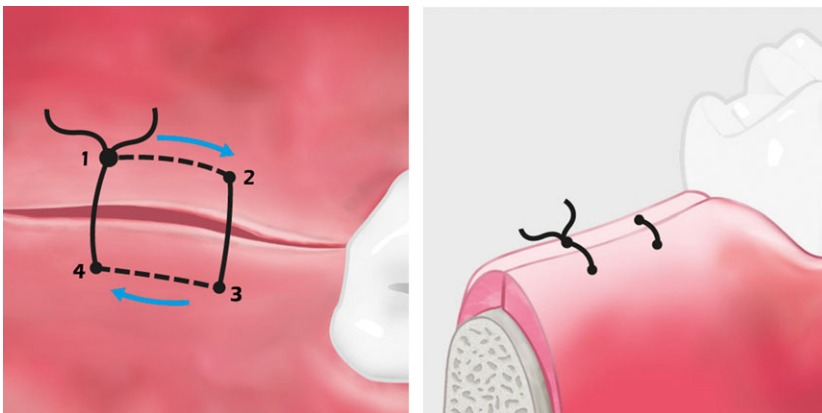


Fig. 7. Horizontal inverting mattress suture that firmly adapts the soft tissue flap to the underlying structures.

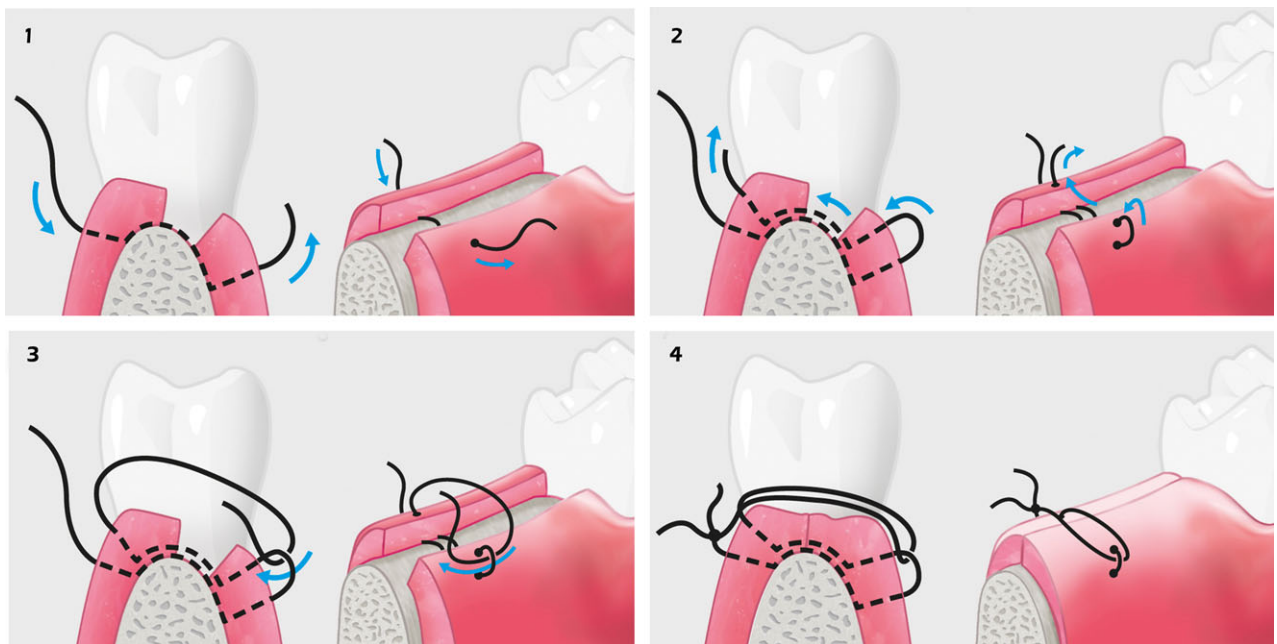


Fig. 8. Modified vertical mattress sutures (according to Laurell), characterized by an in- and everting portion, ideal for interdental tissue closure.

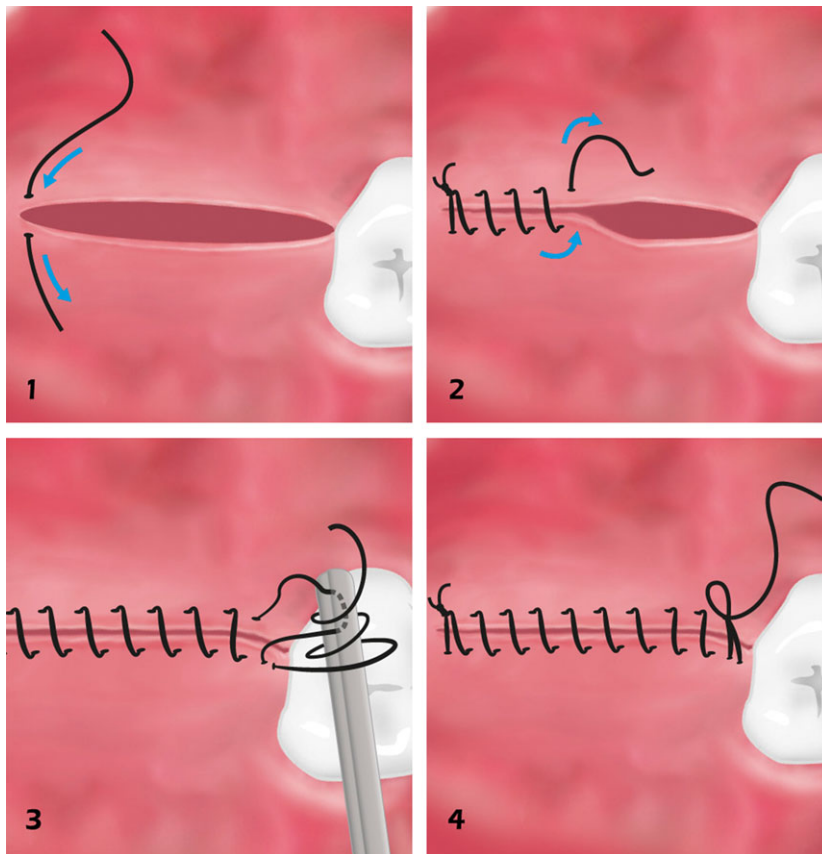


Fig. 9. Continuous suture, characterized by fewer individual suture ties.

its use. This is because of the likelihood that the integrity of the entire surgical site will become compromised if one knot or loop of the suture breaks (Fig. 9). A comprehensive overview and explanation of the commonly applied suture techniques can be downloaded electronically in an app format (36).

Conclusion

Wound healing following periodontal and peri-implant flap surgery at hard, nonshedding surfaces is conceptually a more complex process than wound healing in most other sites of the oral cavity. Owing to the fact that such sites comprise the connective tissue surface of a flap and an avascular surface, such as dentin, titanium, ceramics or other alloplastic materials, careful tissue management and stable flap adaptation are required (47).

Optimal flap stabilization promotes the early formation and organization of a blood clot and consequently ensures that the delicate fibrin clot adheres to the hard, nonshedding wound-bed surface (48). Hence, stabilization and adaptation of the soft tissues covering the wound area with appropriate suturing appears to be a key prerequisite for achieving optimal surgical outcomes (8). There is

evidence that passive flap adaptation can be improved by the use of thinner sutures (6-0 and 7-0) as they will break before the tissues are torn. This, in turn, means that a clinician can control the amount of damage to the tissue by selecting thicker or thinner suture material (7).

As a negative aspect, suturing appears to exhibit a local adverse influence on the blood circulation until sutures are removed. Consequently, as few sutures as absolutely needed to assure stability of the healing wound should be used. They should be left *in situ* according to the individual situation and not as a stereotyped regime, over a period of 7–10 days (24). With the sophisticated surgical procedures applied today, there is a greater need for knowledge with regard to the various types of suturing techniques and materials currently available in order to achieve the above-mentioned goals.

References

1. Bhaskar SN, Frisch J, Margetis PM, Leonard F. Application of a new chemical adhesive in periodontic and oral surgery. *Oral Surg Oral Med Oral Pathol* 1966; **22**: 526–535.
2. Blomstedt B, Österberg B. Fluid absorption and capillarity of suture materials. *Acta Chir Scand* 1977; **143**: 67–70.

3. Blomstedt B, Österberg B, Bergstrand A. Suture material and bacterial transport. An experimental study. *Acta Chir Scand* 1977; **143**: 71–73.
4. Burgess LPA, Morin GV, Voussoughi J, Hollinger JO. Wound healing. Relationship of wound closing tension to scar width in rats. *Arch Otolaryngol Head Neck Surg* 1990; **116**: 798–802.
5. Burkhardt R, Lang NP. Coverage of localized gingival recession: comparison of micro- and macrosurgical techniques. *J Clin Periodontol* 2005; **32**: 287–293.
6. Burkhardt R, Lang NP. In: Lang NP, Lindhe J, editors. *Clinical Periodontology and Implant Dentistry*. Oxford: Blackwell Munksgaard, 2008: 1029–1044.
7. Burkhardt R, Preiss A, Joss A, Lang NP. Influence of suture tension to the tearing characteristics of the soft tissues: an in vitro experiment. *Clin Oral Implants Res* 2008; **19**: 314–319.
8. Burkhardt R, Lang NP. Role of flap tension in primary wound tension of mucoperiosteal flaps: a prospective cohort study. *Clin Oral Implants Res* 2010; **21**: 50–54.
9. Chu CC, Williams DF. Effects of physical configuration and chemical structure of suture materials on bacterial adhesion. A possible link to wound infection. *Am J Surg* 1984; **147**: 197–204.
10. Edlich RF, Panek PH, Rodeheaver GT, Kurtz LD, Edgerton MT. Surgical sutures and infection: a biomaterial evaluation. *J Biomed Mater Res* 1974; **8**: 115–126.
11. Forrest JO. The use of cyanoacrylates in periodontal surgery. *J Periodontol* 1974; **45**: 225–229.
12. Greer RO Jr. Studies concerning the histotoxicity of isobutyl-2-cyanoacrylate tissues adhesive when employed as an oral hemostat. *Oral Surg Oral Med Oral Pathol* 1975; **40**: 659–669.
13. Grisdale J. The use of cyanoacrylate in periodontal therapy. *J Can Dent Assoc* 1998; **64**: 632–633.
14. Gutmann JL, Harrison JW. *Surgical Endodontics*. Boston: Blackwell Scientific, 1994: 278–299.
15. Haaf U, Breuninger H. Resorbable suture material in the human skin: tissue reaction and modified suture technic. *Hautarzt* 1988; **39**: 23–27.
16. Hansen H. Nahtmaterial (suture materials). *Chirurg* 1986; **57**: 53–57.
17. Herod EL. Cyanoacrylates in dentistry: a review of the literature. *J Can Dent Assoc* 1990; **56**: 331–334.
18. Hoexter DL. The sutureless free gingival graft. *J Periodontol* 1979; **50**: 75–78.
19. Kulkarni SS, Chava VK. Comparison of cyanoacrylate and silk sutures on healing of oral wounds-an animal model study. *Indian J Dent Res* 2003; **14**: 254–258.
20. Kulkarni SS, Dodwad V, Chava VK. Healing of periodontal flaps when closed with silk sutures and N-butyl cyanoacrylate: an clinical and histological study. *Indian J Dent Res* 2007; **18**: 72–77.
21. Leknes KN, Selvig KA, Bøe OE, Wikesjö UME. Tissue reactions to sutures in the presence and absence of anti-infective therapy. *J Clin Periodontol* 2005; **32**: 130–138.
22. Lober CW, Fenske NA. Suture materials for closing the skin and subcutaneous tissues. *Aesthetic Plast Surg* 1986; **10**: 245–248.
23. Macht SD, Krizek TJ. Sutures and suturing – current concepts. *J Oral Surg* 1978; **36**: 710–712.
24. Mc Lean TN, Smith BA, Morisson EC, Nasjleti CE, Caffesse RG. Vascular changes following mucoperiosteal flap surgery: a fluorescein angiography study in dogs. *J Periodontol* 1995; **66**: 205–210.
25. Meng MV. Reported failures of the polymer self-locking system (Hem-o-lok) clip: review of data from the Food and Drug Administration. *J Endourol* 2006; **20**: 1054–1057.
26. Meyer RD, Antonini CJ. A review of suture materials. Part I, Part II. *Compendium* 1989; **10**: 260–262, 264–265, 360–362, 364, 366–368.
27. Miller PD. A classification of marginal tissue recession. *Int J Periodontics Restorative Dent* 1985; **5**: 9–13.
28. Moore RL, Hill M. Suturing techniques for periodontal plastic surgery. *Periodontol* 1996; **11**: 103–111.
29. Morin GV, Rand M, Burgess LPA, Voussoughi J, Graeber GM. Wound healing: relationship of wound closing tension to tensile strength in rats. *Laryngoscope* 1989; **99**: 783–788.
30. Mouzas GL, Yeadon A. Does the choice of suture material affect the incidence of wound infection? A comparison of dextran (polyglycolic acid) sutures with other commonly used sutures in an accident and emergency department. *Br J Surg* 1975; **62**: 952–955.
31. Myers MB, Cherry G, Heimburger S. Augmentation of wound tensile strength by early removal of sutures. *Am J Surg* 1969; **117**: 338–341.
32. Pérez M, Fernández I, Márques D, Mayelín Guerra Breña R. Use of N-butyl-2-cyanoacrylate in oral surgery: biological and clinical evaluation. *Artif Organs* 2000; **24**: 241–243.
33. Pini-Prato G, Pagliaro U, Baldi C, Nieri M, Saletta D, Cairo F, Cortellini P. Coronally advanced flap procedure for root coverage. Flap with tension versus flap without tension: a randomized controlled clinical study. *J Periodontol* 2000; **71**: 188–201.
34. Postlethwait RW, Smith BM. A new synthetic absorbable suture. *Surg Gynecol Obstet* 1975; **140**: 377–380.
35. Postlethwait RW, Willigan DA, Ulin AW. Human tissue reactions to sutures. *Ann Surg* 1975; **18**: 144–150.
36. Rasperini G. *The Oral Surgery Trainer (Application Software)*. Berlin, Germany: Quintessence Publishing, 2013.
37. Rothenburger S, Spangler D, Bhende S, Burkley D. In vitro antimicrobial evaluation of coated Vicryl® Plus antibacterial suture (coated polyglactin 910 with triclosan) using zone and inhibition assays. *Surg Infect* 2002; **3**(Suppl 1): 70–87.
38. Salthouse TN. Biologic response to sutures. *Otolaryngol Head Neck Surg* 1980; **88**: 658–664.
39. Selvig KA, Biagotti GR, Leknes KN, Wikesjö UM. Oral tissue reactions to suture materials. *Int J Periodontics Restorative Dent* 1998; **18**: 474–487.
40. Silverstein LH, Kurtzman GM, Shatz PC. Suturing for optimal soft-tissue management. *J Oral Implantol* 2009; **35**: 82–90.
41. Thacker JG, Rodeheaver GT, Towler MA, Edlich RF. Surgical needle sharpness. *Am J Surg* 1989; **157**: 334–339.
42. Tonetti MS, Pini-Prato G, Cortellini P. Effect of cigarette smoking on periodontal healing following GTR in infrabony defects. A preliminary retrospective study. *J Clin Periodontol* 1995; **22**: 229–234.
43. Vargas G, Reger TB. An alternative to sutures. *Plast Surg Nurs* 2001; **21**: 83–85.
44. Varma S, Ferguson HL, Breen H, Lumb WV. Comparison of seven suture materials in infected wounds-an experimental study. *J Surg Res* 1974; **17**: 165–170.

45. von Fraunhofer JA, Johnson JD. A new surgical needle for periodontology. *Gen Dent* 1992; **40**: 418–420.
46. Werfully S, Areibi G, Toner M, Bergquist J, Walker J, Renvert S, Claffey N. Tensile strength, histological and immunohistochemical observations of periodontal wound healing in the dog. *J Periodontal Res* 2002; **37**: 366–374.
47. Wikesjö UME, Nilvéus R. Periodontal repair in dogs: effect of wound stabilization on healing. *J Periodontol* 1990; **61**: 719–724.
48. Wikesjö UME, Crigger M, Nilvéus R, Selvig KA. Early healing events at the dentin-connective tissue interface. Light and transmission electron microscopy observations. *J Periodontol* 1991; **62**: 5–14.
49. Wikesjö UME, Claffey N, Egelberg J. Periodontal repair in dogs. Effect of heparin treatment of the root surface. *J Clin Periodontol* 1991; **18**: 60–64.